Pet rabbit nutrition – structure and function of its gastrointestinal tract

Author : Lesa Thompson

Categories : Vets

Date : June 24, 2013

LESA THOMPSON examines the anatomy and physiology of the gastrointestinal tract in rabbits, and focuses on diet for optimum health in the pet animal

THIS article focuses on the anatomy and physiology of the gastrointestinal (GI) tract in rabbits. Understanding these is of paramount importance when considering rabbit nutrition in captivity, and to prevent pathological conditions seen all too frequently by veterinary practitioners.

Anatomy of the gastrointestinal tract

Beginning cranially, the rabbit oral cavity differs greatly to that of carnivores. Firstly, the aperture is small – making detailed conscious examination impossible. Secondly, the dentition is contrasting, with a dental formula of: incisors 2/1, canines 0/0, premolars 3/2 and molars 3/3. The peg teeth are a smaller second set of upper incisors and are caudal to the first set. At rest, the lower incisors should be just caudal to the upper incisors. All rabbit teeth are rootless and grow continuously at 2mm per week. The long tongue has an elevated portion caudally, called the lingual torus.

The rabbit stomach is thinwalled and accounts for about 15 per cent of the GI tract volume. The cardia has a welldeveloped sphincter, meaning a healthy rabbit cannot vomit. The normal stomach contains a mix of food, fur and fluid.

The small intestine is relatively short. The duodenal position is at an acute angle to the liver. The

bile duct enters the duodenum near the stomach. The pancreatic lobes lie in the mesoduodenum and between the stomach and transverse colon, with the pancreatic duct opening into the duodenum between the transverse and ascending loops.

The jejunal portion of the small intestine is long and convoluted. The terminal ileum enlarges into the sacculus rotundus, containing much lymphoid tissue and macrophages.

The large hindgut comprises the caecum and colon. The caecal wall is thin-walled, contains 40 per cent of the intestinal content and ends in the blind-ending vermiform appendix, which has significant lymphoid tissue content. The proximal (or ascending) colon comprises three taenia (longitudinal muscular bands) that create haustra (sacculations), a single taenia/haustra, and the fusus coli (a 5cm to 8cm thickened section). Protrusions are present within the mucosa in the initial portion of the colon. The fusus coli contains prominent longitudinal folds, numerous goblet cells, and is highly innervated and vascular. The distal colon is 80cm to 100cm long, thin-walled, has a smooth mucosa and is unsacculated.

Gastrointestinal tract physiology

Rabbit incisors slice food, which is then chewed by the cheek teeth, the premolars and molars, which function as a single unit. Caecotrophs (see later) are swallowed intact.

It is normal for fur to be present to some degree in the rabbit’s stomach. Trichobezoars are excess amounts of hair that result in an impaction and occur occasionally in rabbits. However, these are thought to be the result of other pathological conditions, such as dehydration and reduced gastric motility, rather than a primary pathology. Dietary fibre is required to maintain normal gut motility in rabbits.

Water and acid are secreted into the stomach where hydrochloric acid and pepsin begin to digest the ingesta. The pH in adult rabbits is approximately one to two although it rises to three during caecotroph digestion – resulting in effective sterilisation of ingesta en route to the small intestine.

The suckling rabbit has a stomach pH of around 5.0 to 6.5. Milk oil in the doe’s milk acidifies and protects the stomach at this stage of development until the young acquire gut flora, aided by eating the doe’s caecotrophs. The high stomach pH in suckling rabbits permits the healthy bacteria through to the hindgut for colonisation.

The transit of food through the stomach takes approximately three to six hours. Once in the small intestine, digestion and absorption of sugars and protein occurs. Vitamins, proteins and fatty acids are also obtained here from caecotrophs. Amylase is produced in the pancreas, but is also found in saliva and caecotrophs.

Motilin secretion (stimulated by fat and inhibited by carbohydrate) in the duodenum and jejunum

stimulates motility in this region of the GI tract. Bicarbonate secreted into the duodenum neutralises acidic matter from the stomach, while bicarbonate is absorbed in the jejunum. Small intestinal transit time is 10 to 20 minutes in the jejunum and 30 to 60 minutes through the ileum.

The next portion of the GI tract is the caecum, where, ingesta are fermented. The junction between the ileum, caecum and proximal colon are adapted for mixing and separating large quantities of ingesta. The appendix is rich in lymphoid tissue and secretes further bicarbonate to buffer caecal acids.

Again, changes in this portion of the GI tract occur during weaning, with ammonia levels decreasing as the diet changes, the pH becoming more acidic with a general increase in volatile fatty acids (VFA), and individual VFA proportions altering, which results in a change in microbial flora.

Indigestible fibres, such as cellulose and lignin, stimulate most hindgut motility. The fusus coli acts as a pacemaker, controlling motility in the colon to produce hard and soft faeces. This region is regulated by the autonomic nervous system and aldosterone, thus any stress increases adrenaline and may result in caecal stasis and abnormal caecotrophs. Large, solid, indigestible particles are separated and form hard faecal pellets, while liquids and smaller fermentable particles return via antiperistalsis to the caecum for further fermentation.

The formation of hard faeces coincides with feeding activity. This hard faeces phase involves water secretion into the proximal colon along with caecal and colonic contractions to aid mixing and separation. The indigestible material is rapidly moved through the distal colon. During passage through the fusus coli, muscular contractions squeeze water out of the material, and more water, VFA and electrolytes are absorbed into the distal colon before excretion of hard, dry faecal pellets.

Conversely, fermentable particles are moved retrogradely into the caecum. Caecal contents are semi-fluid. The pH varies diurnally – being most alkaline in the morning and most acidic in the afternoon. This portion of the GI tract is a large bacterial fermentation chamber. Bacteroides species are the main microorganisms in the caecum, resulting in production of acetate as the predominant volatile fatty acid.

Besides many other strains of bacteria, a normal healthy caecum will also contain many non-pathogenic protozoa. VFAs are produced by caecal microflora and absorbed as an energy source for the rabbit. However, not all nutrients are absorbed at this stage. Some are packaged as caecotrophs, which contain microorganisms and microbial fermentation products, including amino acids, VFAs and vitamins.

The production of soft caecotrophs involves a change in motility in the colon, so neither separation nor water absorption occur. Material is moved along the colon before separation in the fusus coli and encapsulation in mucus for protection from stomach acidity after ingestion and prior to

excretion.

The process of eating caecal pellets – caecotrophs – is called caecotrophy. These pellets are passed four to eight hours postfeeding (usually at night during a period of rest), eaten directly from the anus and swallowed whole. Some fermentation occurs during the time caecotrophs spend in the gastric fundus. Lysozyme secreted in the colon and incorporated into the caecotrophs enables degradation of microbial protein, and this is absorbed in the small intestine along with the other nutrients contained therein.

The presence of protrusions within the initial portion of the colon increases surface area and, thus, absorption capability and may assist mechanical separation of ingesta.

Diet in the wild

Rabbits are strict herbivores, and wild individuals survive predominantly on grasses and weeds. As outlined previously, their digestive system is adapted for a high-fibre, relatively lowquality, diet.

After initial ingestion, the presence of a second pass system through the GI tract enables rabbits to digest materials along the full length of the tract, including a significant component of bacterial fermentation, before reingestion of a portion of the materials and absorption of nutrients during the second passage.

However, there is a fine balance between rabbit physiology and gut microflora, and both are readily upset by an inappropriate diet or other stressors.

Diet in captivity

Historically, captive rabbits were fed on a range of forage materials similar to their wild counterparts. Pelleted foods have been formulated for largescale rabbit production.

However, the requirements of these animals differ to those kept as pets – for example, pet rabbits will hopefully long outlive the production animals.

Although pelleted foods contain certain nutrients required by rabbits they sometimes fall short on providing a balanced diet – in particular, regarding the presence of sufficient fibre. Pelleted foods also often enable selective feeding, which may lead to problems (see below).

The aim of a balanced diet should be to mimic that for which rabbits have evolved – and is similar to what wild rabbits would consume (see panel on page 12).

Problems that may be the result of inappropriate nutrition

The most common pathology associated with inappropriate nutrition in rabbits is dental disease. Horizontal grooves in the incisors may be the first sign of dental disease associated with malnutrition. Insufficient fibre or abrasive material in the diet will result in malocclusion as the continuously growing teeth wear unevenly.

Such diets containing insufficient or inappropriate fibre (rabbits require both indigestible fibre and fermentable fibre) will also lead to other health problems. Indigestible fibre is necessary for dental exercise and wear, stimulation of appetite and caecotroph ingestion, stimulation of gut motility and foraging to prevent boredom. Fermentable fibre is necessary for healthy caecal microflora, caecal pH and VFA production, caecotroph consistency and prevention of pathogenic bacteria in the caecum.

Weaning is a critical time for rabbits and failure to develop appropriate healthy gut flora can result in bacterial enteritis and enterotoxaemia. The high pH of the suckling rabbit's stomach permits passage of pathogenic bacteria – for example, pathogenic strains of *Escherichia coli* along with healthy bacteria. This is particularly a problem for hand-reared rabbits, which do not receive protective milk oil from a doe's milk and may not have access to adult caecotrophs for healthy colonisation of the GI tract during weaning.

The latter potential problem can be avoided by collecting caecotrophs from an adult rabbit (for example, by putting an Elizabethan collar on the animal overnight) to offer to the young rabbit being handreared. Natural rearing by the doe is preferred and permitting a longer period of weaning, during which time healthy gut colonisation can occur.

After weaning, young rabbits are often subjected to various stresses that may affect GI function. Aside from the increased risk at this time to GI pathogens, such as *Clostridia* species, coccidiosis and *Rotavirus*, changes in housing, diet, and mixing with novel conspecifics may make the animals more susceptible to GI dysfunction and other disease. Providing a suitable diet with sufficient indigestible fibre and minimising stress during this period are important.

High carbohydrate diets inhibit motilin secretion and, therefore, reduce gut motility. The excess glucose in high carbohydrate diets – such as may occur if a rabbit eats an excess pelleted diet or selectively feeds on such a diet – is also a medium for potentially pathogenic bacteria to colonise, such as *Clostridium spiroforme* and *E coli*.

Excess VFAs are produced, which result in a pH decrease, consequently inhibiting healthy flora and permitting proliferation of pathogens. High protein diets reduce caecotroph consumption and also lead to gut motility problems.

Any conditions that reduce caecotroph ingestion will significantly alter the rabbit's nutrient uptake and lead to GI disorders. These conditions may include dental disease, arthritis, neurological disease and obesity.

Summary

Provision of suitable nutrition will help reduce the risk of many diseases in captive rabbits. An understanding of the species' GI anatomy and physiology, combined with consideration of the wild diet for which this evolved, will enable the veterinary practice to provide good advice to rabbit owners.

Further reading

- Harcourt-Brown F (2002). *Textbook of Rabbit Medicine*, Butterworth Heinemann, Oxford.
- Meredith A and Flecknell P (2006). General biology and husbandry, *Manual of Rabbit Medicine and Surgery* (2nd edn), BSAVA, Gloucester: 1-17.
- O'Malley B (2005). Rabbits, *Clinical Anatomy and Physiology of Exotic Species: Structure and function of mammals, birds, reptiles and amphibians*, Elsevier Saunders, Edinburgh.

Suggested diet for pet rabbits

• Good quality hay should form the basis of the diet. The hay should be sweet-smelling and not mouldy or dusty.

• Vegetables (particularly leafy greens) or weeds may be given in moderation. Suitable vegetables include : spring greens, kale, cauliflower leaves, sprout peelings and broccoli. Safe wild plants include : dandelion leaves, chickweed, clover, sow thistle, trefoil and vetch.

• Avoid vegetables with a high sugar content, such as carrots (though the green leaves on carrot tops are acceptable).

• Potentially toxic plants include : foxglove, irises, ivy, ragwort, yew or large quantities of kale, cabbage or spinach.

• Tree leaves from fruit trees and hazel can be eaten.

• A very small quantity of pelleted or extruded diet may be given. Extruded diets are preferable as the rabbit cannot select high carbohydrate portions.

• Always provide fresh water – either in a bowl or sipper bottle.

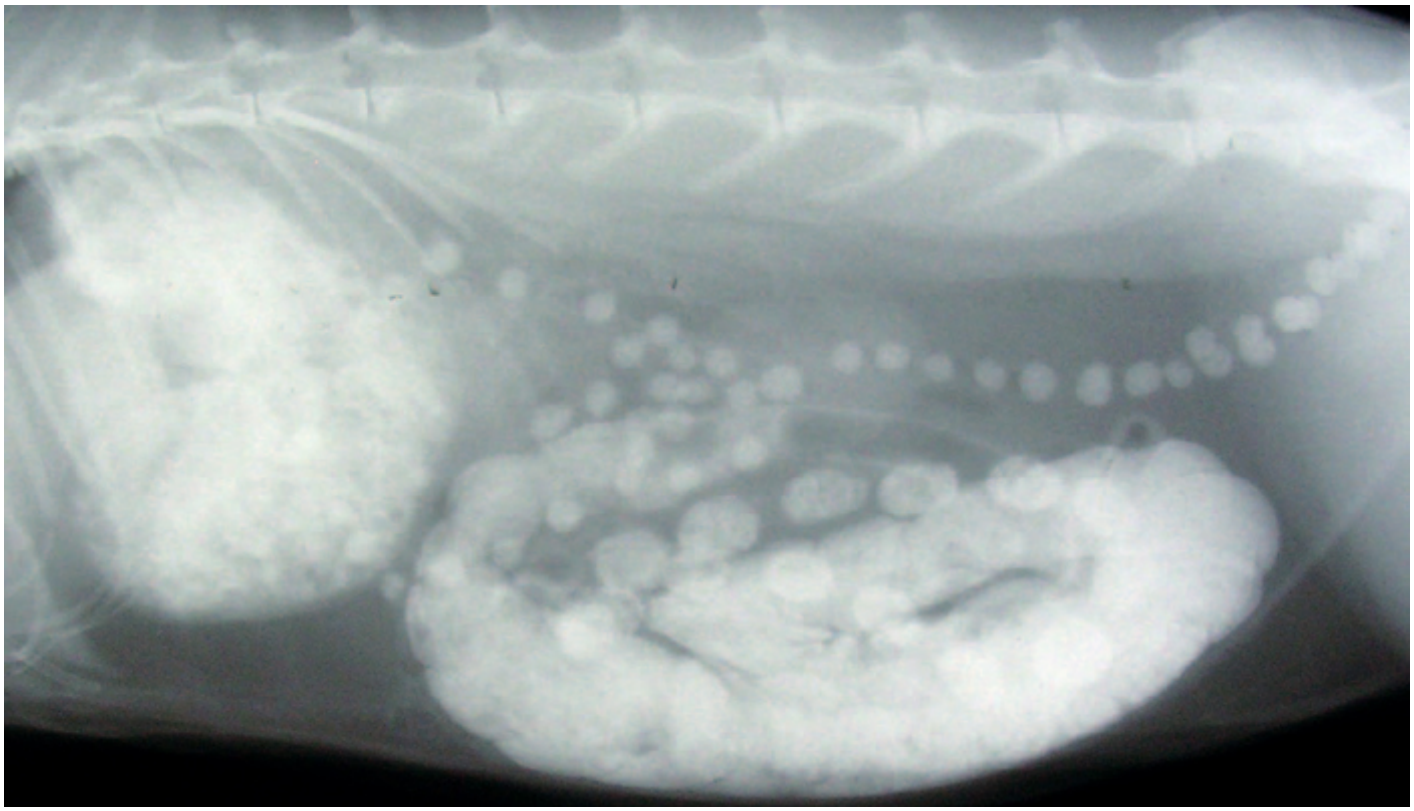

Lateral abdominal radiograph approximately six hours after administering barium orally. Barium is obvious within the stomach, caecum and colon. Faecal pellets containing barium are also present.

Rabbits should be offered a selection of foods to encourage eating during hospitalisation – including good quality hay, fresh water, and pelleted foods. For a normal balanced diet, only small amounts of pelleted/ extruded food should be offered. Inset: a rabbit caecotroph.

Inset: a rabbit caecotroph.

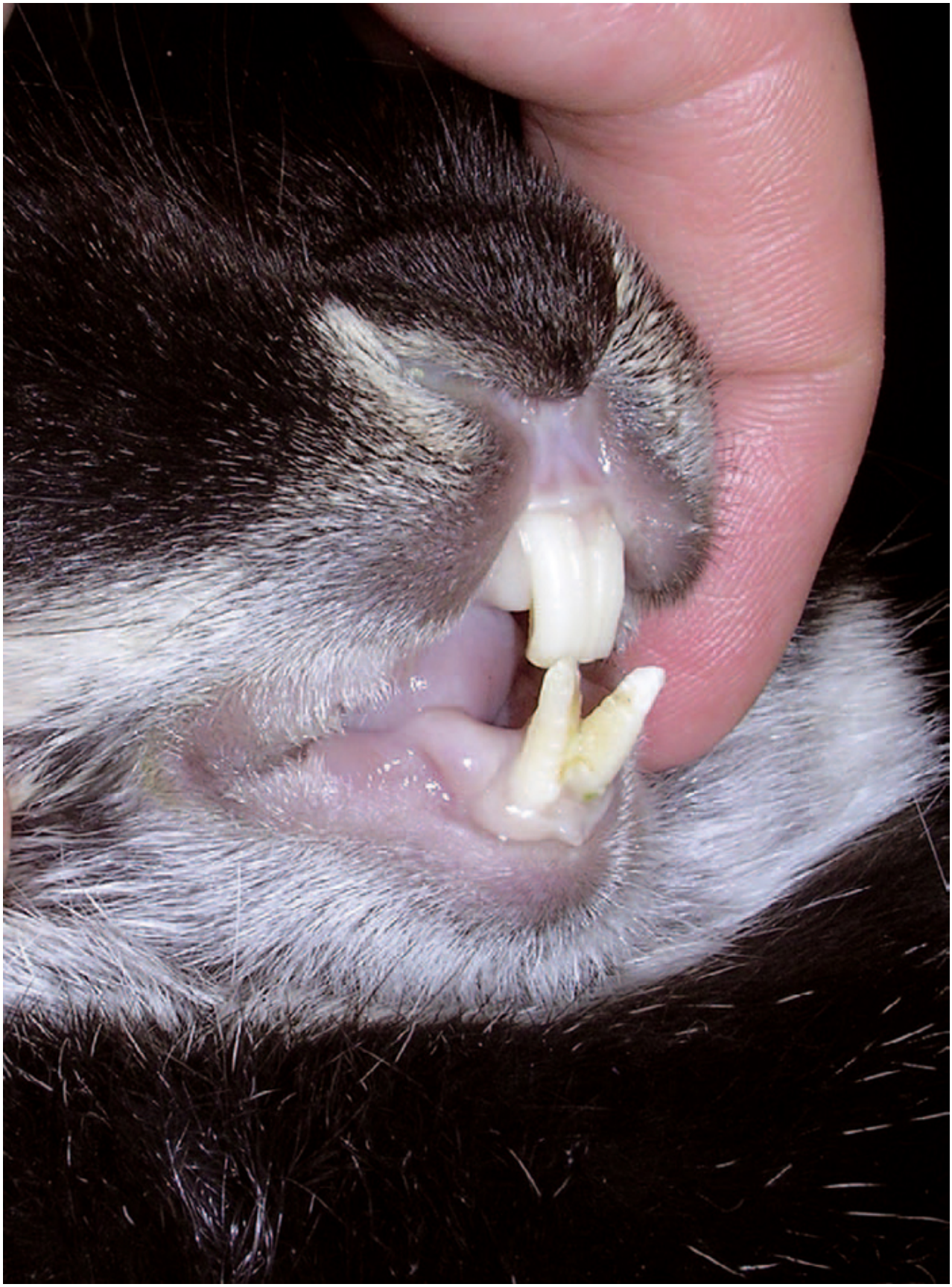

Incisor malformation is thought to be associated with insufficient dietary fibre.