EVALUATING POOR PERFORMANCE

Author : Shelley Down

Categories : Vets

Date : December 8, 2008

SHELLEY DOWN discusses diagnostic modalities for horses, and says such investigations may be unrewarding.

EVALUATION of the underperforming horse requires time, patience and the use of a variety of diagnostic techniques. The owner should be advised that an investigation may be costly, time consuming and unrewarding. There may also be a degree of over expectation from the owner.

History

A thorough history is crucial to understand the owner ’s expectations, complaint and provide any clues to the cause of the problem. Questions should include:

• signalment;

• the circumstances under which the reduction in performance happens;

• previous and current training regimes and/or techniques;

• any change in competition level, training, surface, rider, tack or management;

• any change in the horse’s clinical appearance, such as muscular coverage, symmetry, hoof changes, position at rest and activity in the field;

• any specific resistance, loss of strength, unevenness or tension when ridden; and

• whether duration, type or timing of exercise, or surface type affects performance.

Video assessments, trainer reports and competition results may be helpful.

Clinical examination

A clinical examination should be done in a thorough and methodical manner, and include auscultation of the heart, lungs and trachea (with the use of a re-breathing bag), palpation of the larynx, oral inspection and full orthopaedic examination.

Dynamic evaluation

The horse should be assessed in-hand on both soft and hard surfaces. Musculoskeletal pain may only become apparent if a variety of surfaces are used. For example, a horse with bilateral foot pain may only be short striding or lame on a hard surface.

The horse should also be ridden by the usual rider whenever possible. This allows for examination of the horse's movement and temperament under the conditions that the owner perceives there is a problem, and also provides an opportunity to assess horse-rider interaction and rider ability. It is useful to see the horse tacked up and mounted, as immediate shortening of stride or cold-backed behaviour may become apparent.

Various rider-associated problems can result in the horse showing compensatory gait changes, resentment, confusion or a reduction in movement quality. A rider that is crooked, unbalanced or too large for the saddle or horse may limit the horse's physical ability to perform in an athletic capacity. An inexperienced, nervous or tense rider can provide confusing signals, resulting in the horse losing confidence and gaining behavioural problems, with or without physical limitations. For example, inappropriate aids into fences may cause the horse to refuse.

A different rider may alleviate some or all of the symptoms if they are rider induced, and mislead the clinician. A good rider can also correct the horse, removing clinical signs that may only be seen under saddle. It is, therefore, prudent to see the horse ridden by both the usual rider and another skilled rider, and assess any differences observed. The riders should be questioned about what they can feel when riding the horse, as subtle signs – such as shortening of stride, alteration in contact or restriction through the back – may be clearly felt by the rider, although not observed from the ground. If the veterinary surgeon is a skilled rider, he or she may ride the horse to feel what has been described, obviously with agreement from the owner. If the veterinary surgeon is not experienced in the type and use of the horse, or in assessing the rider, it may be worthwhile to have another professional oversee the ridden examination.

Horses often require repeat examination under saddle, as clinical signs may be different on the day of arrival compared to the owner's description. For example, horses with sacroiliac region pain are sometimes worse after travel, and noted by the owner to be worse when the horse arrives at shows. Therefore, the animal is worse on arrival at the clinic (Dyson, personal communication). Sometimes, the horse is better than described – for example, the horse may be exuberant under saddle in new surroundings.

The owner should be asked if the presentation is typical of that about which he or she has a complaint. To ascertain if clinical signs are the result of pain, a dose of 4.4mg/kg of phenylbutazone can be given twice daily for up to seven days (if results are not apparent after two to three days), and the horse's performance reassessed (Dyson, 2003).

Further diagnostics

• Change the tack – as ill-fitting equipment may make the horse unwilling to go forward into a contact, or restrict correct movement under saddle, and/or result in a behavioural change (Figure 1).

• When lameness is present, diagnostic analgesia and imaging should be carried out. After analgesia, seeing the horse being ridden and asked to undertake problematic exercises is ideal. The lameness may be the primary cause of poor performance, but may also be secondary to compensation of both the horse and the rider, so it is important to assess if the performance improves with loss of the lameness alone.

• Because of diagnostic analgesia, if lameness is not apparent, there may be reduced stride length, "push", collection or power, which may result in reduced movement and ability. For example, bilateral analgesia of the front feet may eliminate a shortened stride presentation, and reveal a more extravagant movement and better contact. Bilateral analgesia of the distal tarsal joints, or origin of the suspensory ligaments, may eliminate lack of "push" from behind and improve tarsal compression.

• Nuclear scintigraphic examination may be used as an adjunct to other imaging modalities and may highlight areas of abnormal bone turnover. It is a useful modality for assessing areas difficult to examine clinically, such as the sacroiliac joint region.

• Perform radiography and ultrasonography of clinically abnormal areas, and those that are responsive to analgesia. l Use endoscopy for the upper respiratory tract (URT).

• Tracheal and bronchoalveolar lavage may be used to look for underlying inflammation and/or infection or exercise-induced changes (such as exerciseinduced pulmonary haemorrhage – EIPH).

• Haematological and biochemical analysis may reveal abnormalities. Cardiac troponin-I activity may be assessed (an indicator of myocardial malfunction).

Observe the horse during and after fast work – a high-speed treadmill test (HSTT, Figure 2) may be required to assess the horse at speed appropriately.

• URT evaluation should be undertaken during fast work, to assess for a dynamic obstruction. This can be done via use of endoscopy during a HSTT.

• Use of a telemetric ECG during exercise and the recovery period may reveal an exerciseinduced arrhythmia.

• Echocardiography pre and post-exercise may show reduced fractional shortening (indicating left ventricular dysfunction).

• Muscle enzymes should be re-assessed at between six and 24 hours post-exercise to ascertain if an exercise-induced myopathy has occurred. Creatinine kinase levels peak at six to 12 hours and aspartate aminotransferase levels peak at 24 to 48 hours. Blood lactate concentrations pre and post-exercise may be of use.

• Gastroscopy can be used for gastric ulceration detection.

• An oral examination should be performed to rule out an abnormality that may result in a horse being unwilling to accept contact. An oral examination may reveal lacerations or scarring to the tongue or lips, which could relate to an inappropriate or poorly-fitting bit, or poor handling by a rider.

Specific causes of poor performance

• **Musculoskeletal**

– **Lameness**

Any lameness can decrease the performance ability of a horse. Lameness may be subtle and not easily appreciable to the eye, especially if bilateral. Common causes of lameness-associated poor performance are bilateral foot pain, bilateral metacarpo and/or metatarsophalangeal pain, bilateral proximal suspensory desmitis (fore or hindlimb) or bilateral tarsometatarsal/centrodistal joint pain.

– **Back or sacroiliac joint region pain.**

Back and sacroiliac joint region pain may be the primary cause of poor performance, or may be secondary to another problem. Horses often change and adapt the way they move if they have musculoskeletal pain, resulting in greater pressure being placed on other areas. For example, a horse may have clinically “silent” impinging dorsal spinous processes, which the owner would be unaware of. If the horse then develops an area of pain, resulting in the horse compensating for this by changing the way it moves, then these impinging dorsal spinous processes may become active

and painful.

The horse may then show back stiffness, pain and other clinical signs, such as bucking, and it is these that may alert the rider to a problem.

Alternatively, hindlimb lameness may cause the horse to change its gait in a compensatory manor, resulting in pain arising in the sacroiliac joint region. Common causes of back pain and/or restriction that instigate poor performance include impinging dorsal spinous processes and osteoarthritis of the thoracic and/ or lumbar facet articulations.

– Exertional myopathies

Clinical signs of stiffness, agitation, pain, increased heart rate and body temperature following exercise are usually obvious to the owner or clinician. However, subclinical myopathy may be harder to recognise. Myopathy may present as progressive agitation with work, with or without loss of action (Dyson, 2003).

Cases may be diagnosed by assessing muscle enzymes following exercise. Linear striations of increased radiopharmaceutical uptake within musculature on scintigraphic examination may be seen (Figures 3 and 4). Fractional electrolyte excretion and muscle biopsies may be required to ascertain the underlying cause and determine appropriate treatment. Two common forms of exercise-related myopathies are recurrent exertional rhabdomyolysis and polysaccharide storage myopathy – both have underlying genetic causes.

– **Radiculopathy**

Compression of spinal nerve roots may result in pain and muscle weakness. Clinical signs may be intermittent, or wax and wane. Electromyography, muscle biopsies and imaging may aid diagnosis after ruling out other musculoskeletal disorders.

Clinical signs of poor performance resulting from musculoskeletal pain can manifest in a variety of ways – see Table 1.

• **Upper respiratory tract**

Respiratory noise heard by the rider or clinician during exercise may be indicative of a dynamic obstruction. Endoscopy at rest may give an indication of the type of obstruction. Endoscopy during a HSTT may be required to define the type and extent of obstruction. Types of dynamic upper airway obstruction are listed below, in frequency of occurrence (Lane et al, 2006):

– dorsal displacement of the soft palate (Figure 5);

– palatal instability;

– axial deviation of the aryepiglottic folds;

– arytenoid cartilage collapse (Figure 6); and

– vocal cord collapse.

It must also be noted that these are often found in combination.

• **Lower respiratory tract**

Recurrent airway obstruction, inflammatory airway disease and EIPH may be causes of reduced performance, and can be diagnosed following auscultation, tracheal and bronchoalveolar lavage, and endoscopy following exercise, with or without radiography and/or ultrasound.

• **Cardiac**

– **Murmurs**

Murmurs may be auscultated at rest, and can be evaluated using echocardiography. Mild mitral valve regurgitation is well tolerated (Mitten, 1996). Severe valvular regurgitation during exercise will result in poor performance, and chamber enlargement secondary to regurgitation may predispose to arrhythmia.

– **Arrhythmias**

A supposedly fit horse with atrial fibrillation (Figure 7) may reach fatigue quicker and more easily than the owner would expect. The animal may also show delayed recuperation after exercise. An ECG will provide a definitive diagnosis, but echocardiography should also be undertaken to look for any underlying chamber enlargement.

Arrhythmias may only become apparent during or following exercise with the use of a telemetric ECG. Examples are paroxysmal atrial fibrillation and premature ventricular and supraventricular beats (Martin et al, 2000 and Jose-Cunilleras et al, 2006). The effect on performance of the above premature beats remains debatable. However, it can be assumed that these may indicate exerciseinduced myocardial hypoxaemia or ischaemia, and may limit performance. Bradyarythmias, such as second-degree atrioventricular block (AVB) or third-degree AVB, generally result in severe exercise intolerance.

– **Myocardial disease**

Left ventricular dysfunction has been noted as a cause of poor performance (Martin et al, 2000), and may indicate pre-existing myocardial disease.

• Gastric ulceration

Evidence of ulceration is seen on gastroscopy (Figure 8) following 12 hours of starvation (Franklin et al, 2008), or may be indicated if there is a response to symptomatic treatment. In conclusion, the poor-performing horse is a complex and challenging case. Methodical and patient examination with adjunctive diagnostic aids will help the clinician reach a conclusion, whether it is a clinical condition, rider problem or owner over-expectation.

References

- Dyson S (2003). Poor performance and lameness. In Ross M W and Dyson S J (eds), *Diagnosis And Management Of Lameness In The Horse* (first edn), Saunders, St Louis: 828-832.
- Franklin S H, Brazil T J and Allen K J (2008). Case report: poor performance associated with equine gastric ulceration syndrome in four thoroughbred racehorses, *Equine Vet Edu* **20**(3): 119-124.
- Jose-Cunilleras L E, Young L E, Newton J R and Marlin D J (2006). Cardiac arrhythmias during and after treadmill exercise in poorly performing thoroughbred racehorses, *Equine Vet J (Equine Exercise Physiology Supplement)* **36**: 163-170.
- Lane J G, Bladon D R M, Little J R J and Franklin S H (2006). Dynamic obstructions of the equine upper respiratory tract. Part one: observations during high-speed treadmill endoscopy of 600 thoroughbred racehorses, *Equine Vet J* **38**(5): 393-399. Martin B B, Reef V B, Parente E J and Sage A D (2000). Causes of poor performance of horses during training, racing or showing: 348 cases, *JAVMA* **216**(4): 554-558.
- Mitten L B (1996). Cardiovascular causes of exercise intolerance, *Vet Clin North Am Equine Prac* **12**: 473-494.

Figure 1. A horse showing evasive behaviour.

Figure 2. A patient on a high-speed treadmill.

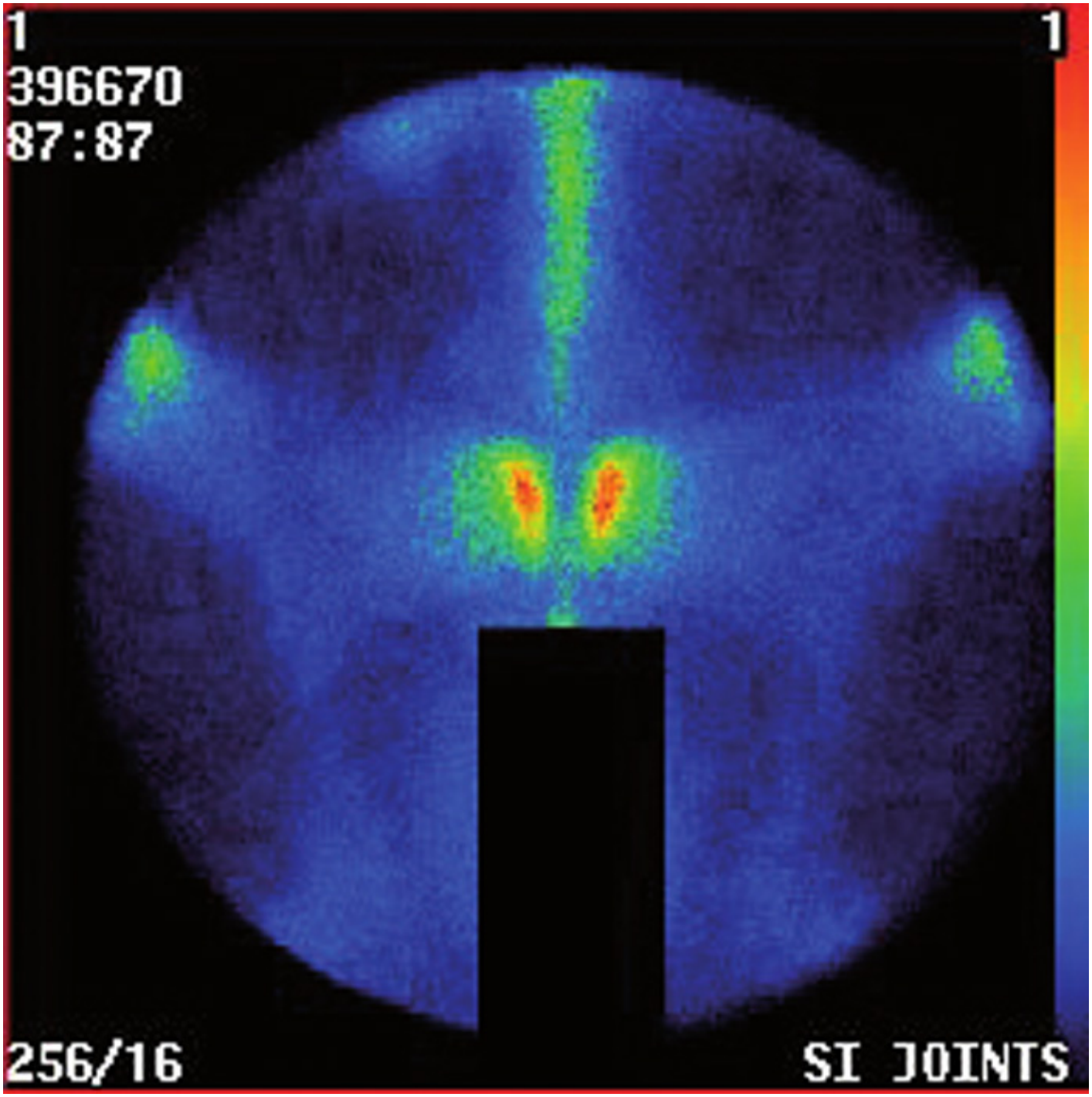

Figure 3 (left). Normal scintigraphic image of a pelvis viewed from above, centring over the tubera sacrale.

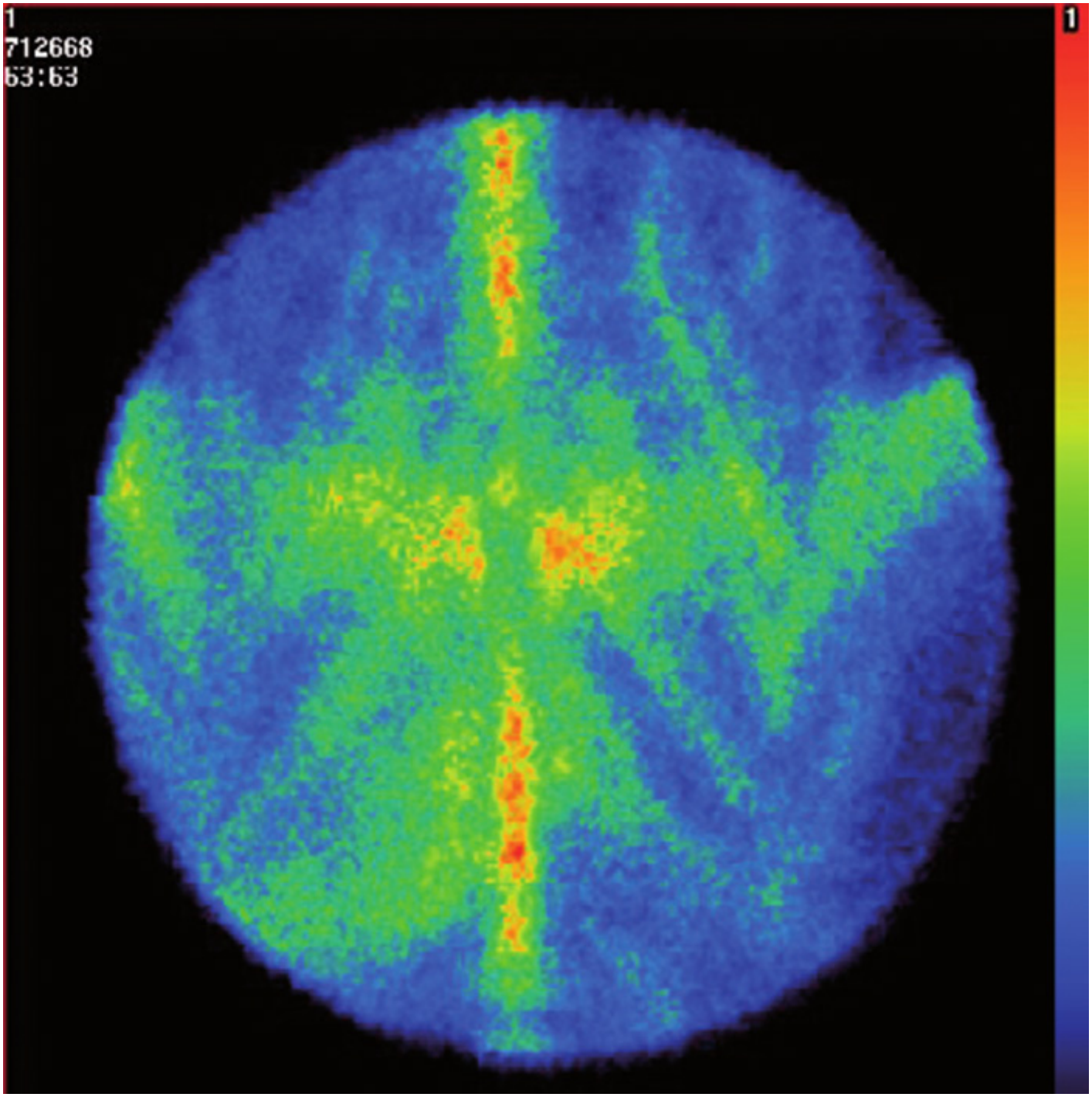

Figure 4 (right). The same view as Figure 3, in this instance showing linear striations of increased radiopharmaceutical uptake in the gluteal musculature consistent with a myopathy.

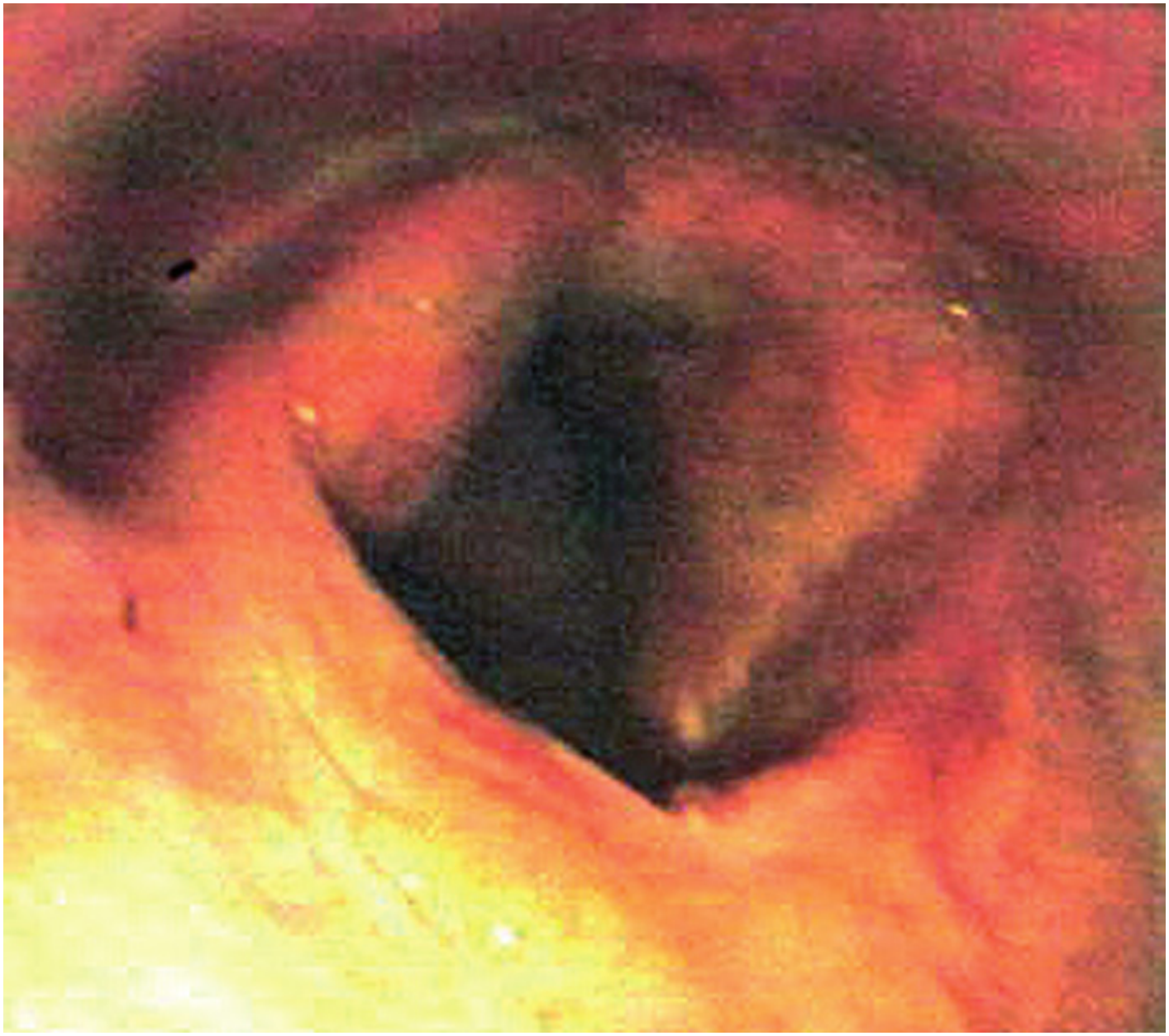

Figure 5. Dorsal displacement of the soft palate, viewed endoscopically.

Photo: TIM GREET.

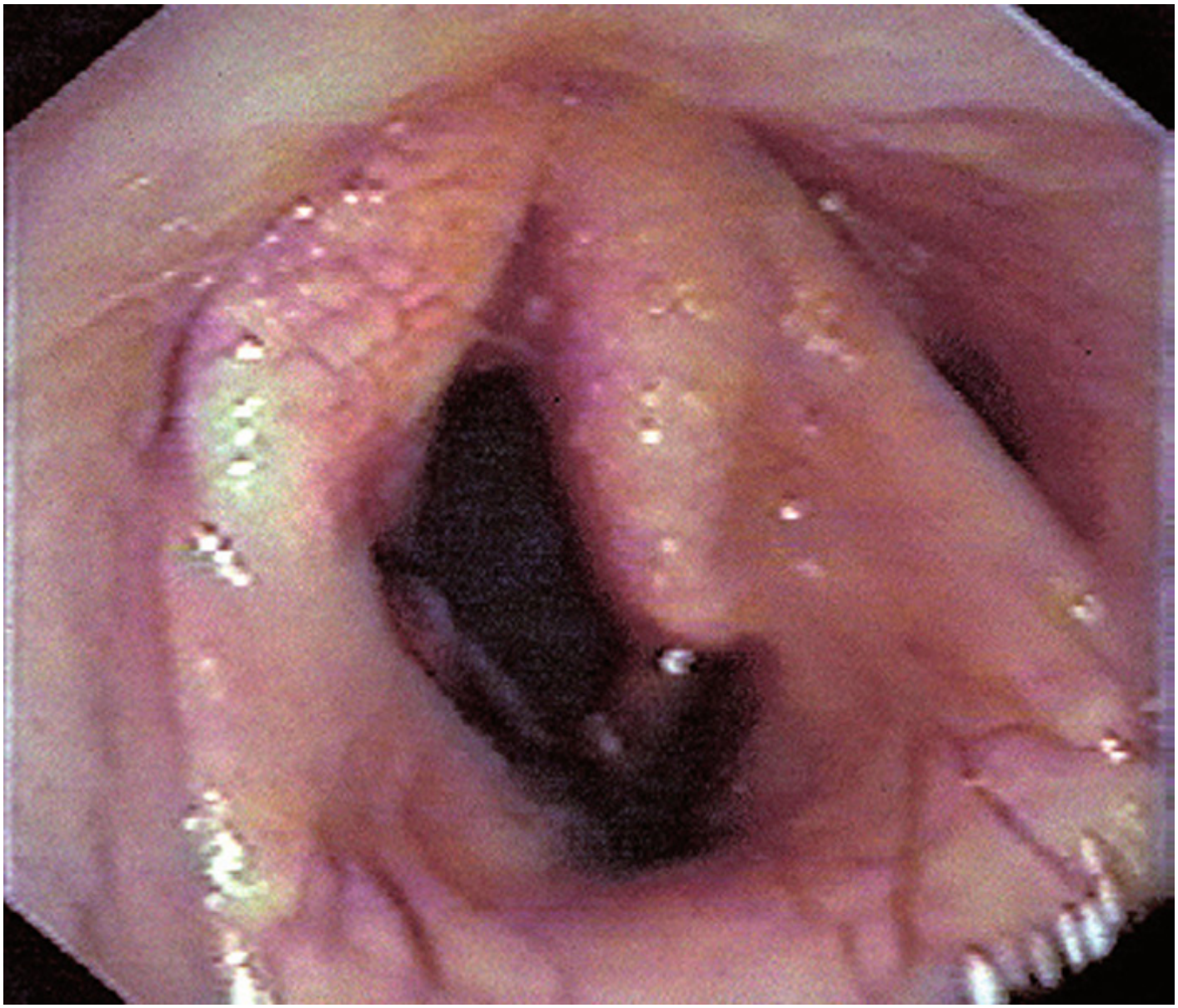

Figure 6. Left laryngeal hemiplegia, viewed endoscopically.

Photo: TIM GREET.

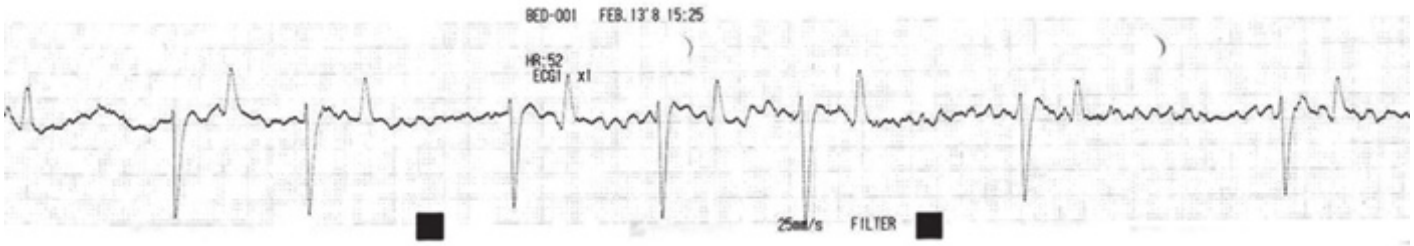

Figure 7. Atrial fibrillation. Note fibrillation (f) waves, irregular R-R interval and lack of P waves.

Figure 8. Gastric ulceration viewed on gastroscopy.

Photo: MEREDITH SMITH.

Area of problem	Clinical signs
Forelimb lameness (also see foot pain)	◆ Unwillingness to work on a specific rein. The head may be held to the outside of a circle ◆ Unwilling to work on the bit† ◆ Loss of action*† ◆ Reluctance to jump "drop" fences. ◆ Change in shape over a fence. The horse may jump "flatter" than usual*† ◆ Stiffness (often due to a bilateral problem)*† ◆ Unwilling to perform medium or extended work*†
Foot pain	◆ Not going forward. The horse may feel short to ride, or resent specific movements. This may be exacerbated on hard or uneven surfaces ◆ Stopping at fences. The horse is unwilling to take off or land, as the horse associates this with greater pain ◆ Not making the distance in combinations. The horse lands steeper than usual to avoid pain and, as a result, cannot make the distance to the next fence ◆ Always landing on the same leading leg and/or reluctance to land on the other forelimb. Peak ground reaction forces are greater in the trailing leg and, therefore, the lead leg is usually the less affected or non-lame leg (Dyson, 2003). This may not be true of all forelimb lameness, such as suspensory apparatus injury
Hindlimb lameness	◆ Not jumping straight and/or drifting to one side over fences. This may reflect hindlimb lameness ipsilateral to the direction of drift ◆ Loss of hindlimb power and/or "push" and impulsion ◆ Difficulty in performing flying changes (or changes are late) ◆ On the forehand† ◆ Saddle slips to one side
Thoracolumbar or sacroiliac pain	◆ Stiffness ◆ Bucking ◆ Changing legs and becoming disunited in canter, or leading with the wrong lead ◆ Kicking out
* indicates also seen with, or in combination with, hindlimb lameness † indicates also seen with, or in combination with, back and/or pelvic pain	

Table 1. Clinical signs associated with musculoskeletal problems