Bearded dragon with periodontal disease: exotic practice challenge

Author : Brigitte Reusch

Categories : Vets

Date : June 8, 2009

Brigitte Reusch describes an underweight lizard that was treated with ultrasonic scaling and dietary modification, and explains why reptiles with acrodont dentition are predisposed to periodontal conditions

THIS interesting case highlights the challenges of treating this exotic species.

The inland bearded dragon (*Pogona vitticeps*), also known as the central bearded dragon, is a species of agamid lizard that is native to the semi-arid woodland, arid woodland and rocky desert regions of Australia.

They are commonly kept as pets and exhibited in zoos. Their life span can be up to 12 years and they typically weigh up to 500g at adult size.

Presentation

An eight-year-old male inland bearded dragon presented with a three-month history of decreased appetite (with selective feeding of soft fruit and mealworms), 10 per cent loss in body weight, and mandibular swelling. The diet offered also included crickets and vegetables ([Table 1]).

The lizard was housed alone in a medium-sized vivarium measuring approximately 45cm× 76cm×60cm. Temperatures in the vivarium ranged from 35 to 40ºC in the hot spot during the day, reducing to 25 to 27ºC during the night. The humidity ranged between 30 and 40 per cent. A broad-

spectrum 100W ultraviolet light provided a 12-hour photoperiod.

On clinical examination, the bearded dragon was alert, but in thin body condition with prominent pelvic bones and a bodyweight of 380g.

Oral examination revealed bilateral mandibular swelling, moderate erythema and severe gingival recession with pocketing in the caudal third of the mandibles (Figure 1).

Calculus deposition and purulent material were found on the mandibular and maxillary arcade, primarily on the exposed bone and in the mandibular pockets.

No other abnormalities were found on examination.

Further diagnostics and treatment

A blood sample was obtained from the ventral coccygeal vein using aseptic venipuncture. Conscious dorsoventral and horizontal lateral radiography of the skull were performed (Figures 2 and 3). Radiography, haematology and biochemistry were all unremarkable.

A diagnosis was made of severe bilateral periodontal disease, primarily involving the mandibular dental arcade with some disease on the maxillary arcade. There was no evidence of osteomyelitis.

Premedication with 0.4mg/ kg butorphanol was given intramuscularly and the lizard was maintained at an environmental temperature of about 30ºC for 20 minutes. Anaesthesia induction was achieved by face mask. Intubation was carried out with a 2mm endotracheal tube, and ventilation was provided using five per cent isoflurane and 1.0L/ minute oxygen in a pressuredriven small animal ventilator.

Anaesthesia was maintained using 1.5 to two per cent isoflurane in 1.0L/minute oxygen. Intermittent positive-pressure ventilation was provided at a frequency of 10 breaths per minute at 5cm H_2O throughout the anaesthetic to mimic previously observed resting respiratory rates and coelomic excursions.

Monitoring included audible doppler ultrasonography to monitor the heart, pulse oximetry positioned in the oesophagus and cloacal temperature using a vital scan monitor.

A deep swab of the periodontal pocket was taken for bacterial and fungal culture; this was performed at both 25ºC and 37ºC. Antibiotic sensitivity testing was also carried out.

Ultrasonic scaling was performed on both the maxillary and mandibular dental arcades to remove the calculus. After scaling, moderate bilateral gingival hyperplasia was revealed on the mandibular dental arcade. The gingival pockets were flushed with 0.1 per cent chlorhexidine acetate oral

solution; this was continued daily for four weeks.

Ceftazidime 20mg/kg, given subcutaneously every 72 hours, was started one week prior to the procedure and continued for a further four weeks. Anaesthetic recovery was unremarkable, and spontaneous respiration resumed within 30 minutes of the isoflurane being turned off.

Dietary modification was initiated. The lizard was fed an increased proportion of harder and larger invertebrates and firm vegetables. The frequency of feeding firm fruit was also decreased (Table 1). These modifications were accepted within a few days.

The aerobic and anaerobic bacterial culture was negative; however, a heavy growth of *Candida albicans* was isolated. Itraconazole 5mg/kg was given orally every 24 hours for seven days. Re-examination of the patient after four weeks found no gingival erythema or purulent material, although the gum recession was unchanged.

Discussion

Periodontal disease is common in captive lizards with acrodont dentition, such as agamids and chameleons[1].

Unlike pleurodont teeth seen in most lizards and all snakes, acrodont teeth are not regularly replaced and are simple triangular teeth ankylosed to the mandibles and maxilla.

A longitudinal ridge of bone, only covered by a thin layer of stratified squamous epithelium, is exposed between the teeth and gingival margin. There is no periodontal ligament. This exposed bone is a common site for plaque and bacterial deposition, leading to periodontal disease.

This case illustrates the typical presentation of an inland bearded dragon – a commonly kept agamid – with periodontal disease. The aetiology of this disease in lizards with acrodont dentition appears to be primarily due to an inappropriate captive diet. A survey of 21 wild-caught agamids and five chameleons found no evidence of periodontal disease[2], whereas a case report describing this condition in 42 captive agamids and chameleons has been published[1].

The soft diet of the bearded dragon in this case study required minimal mastication, thereby predisposing it to plaque accumulation on the exposed bone and gingival margin.

As the condition progressed, the other clinical signs developed. The gingival recession and pocket formation seen ventral to the bone was impacted with calculus and purulent material. This can often be a site for food impaction. In advanced cases, subcutaneous abscessation and severe osteomyelitis with pathological fractures may be seen. This was not seen in this case.

Other factors that may cause periodontal disease in lizards include immunocompromise due to

concurrent disease or environmental stress and malnutrition. Historical findings of selective feeding of soft food and progressive weight loss are typical for this insidious condition, where disease is often advanced on first presentation.

Early stages of the disease are commonly mistaken for stomatitis. Gingival recession, pocket formation and gingival hyperplasia indicate severe chronic periodontal disease.

Progression to systemic disease with septicaemia, pneumonia and hepatic thrombosis may be seen in some cases[3], but not in this example.

An increase in anaerobes (for example, *Bacteroides* species) and spirochetes is reported in agamid lizards with periodontal disease[1]. No bacterial growth was achieved on culture of the deep swab taken from this case. This is not uncommon with samples sent in the post, as *Bacteroides* species rapidly die and may not be detected.

Competition for nutrients in the transport media may also cause culture failure. In this case example, the heavy fungal growth of *C albicans* probably affected the culture. *Candida* species was found to be the most common yeast isolated from a survey of 91 reptiles[4]. *C albicans* and *C tropicalis* have been associated with stomatitis in lizards, with *C albicans* having the highest virulence. Mycotic disease is seen in immunocompromised reptiles. This case had both chronic disease and malnutrition; therefore, the lizard may have been immunocompromised. As yeasts are common oral commensals of reptiles[3],[4], a diagnosis of mycotic infection should, where possible, be made on histopathology. Biopsy was not considered appropriate for this case due to the location, chronicity and severity of disease.

Treatment was aimed at physical removal of the calculus, purulent material and a presumptive secondary mixed bacterial and fungal infection. Systemic ceftazidime and itraconazole and topical chlorhexidine were instigated and a good clinical response was seen within four weeks.

Modification to a diet that requires more mastication has been shown to reduce plaque formation and, in mild cases, prevent recurrence[1]. A regular dental examination every six months has been scheduled.

Conclusion

This case demonstrates a typical presentation of a common condition seen in captive inland bearded dragons. The prognosis for recurrence of periodontal disease for this lizard is poor, as the gingival recession is permanent and the pocket formation makes it prone to calculus accumulation. However, dietary modification and regular dental scaling should manage the condition and prevent further progression to osteomyelitis, which would carry a grave prognosis.

• Although few drugs are licensed for reptiles, the author notes that the use, in this species, of

medications mentioned in this article has been widely reported.

• The author thanks Sharon Redrobe and staff at Bristol Zoo Gardens for their contribution.

• The author, along with Kevin Eatwell, will discuss exotic emer gencies at a CPD event in Newcastle on June 25. For full details, visit www.vet-cpd.co.uk

References

- 1. McCraken H E (1999). Periodontal disease in lizards. In: Fowler M E and Miller E R (eds), *Zoo and Wild Animal Medicine: Current Therapy* (4th edn) W B Saunders: Philadelphia: 252-257.
- 2. McCraken H E and Birch C A (1994). Periodontal disese in lizards, *Proceedings of the American Association of Zoo Veterinarians* , Pittsburgh.
- 3. Redrobe S and Frye F L (2001). Hepatic thrombosis and other pathology associated with severe periodontal disease in the bearded dragon (*Pogona vitticeps*), *Proceedings of the Association of Reptile and Amphibian Veterinarians*: 105-107.
- 4. Kostka V M et al (1997). Review of the literature and investigations on the prevalance and consequences of yeasts in reptiles, *Vet Rec* **140:** 282-287.

Figure 1. The patient had periodontal disease on the mandible.

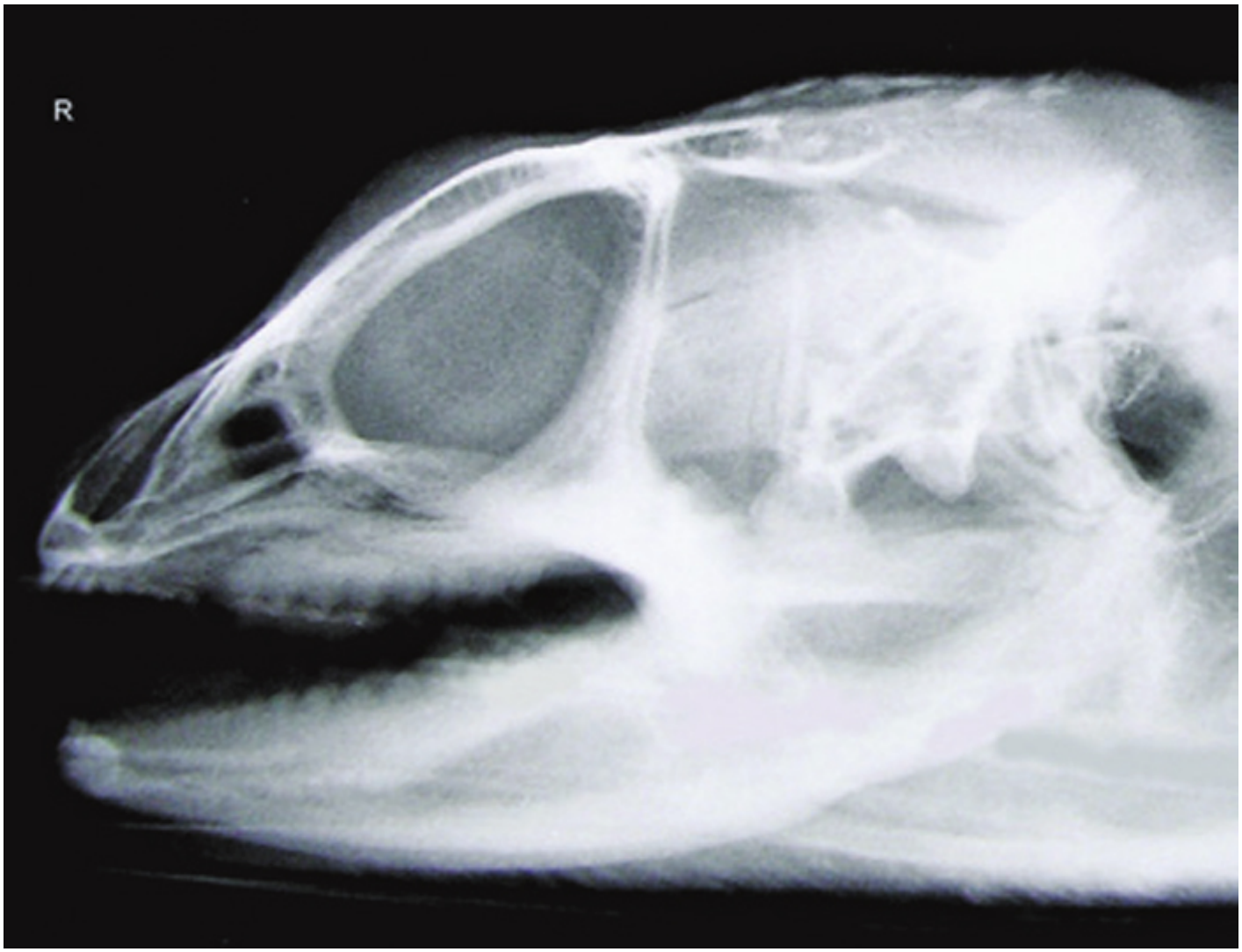

Figure 2 (above). Lateral horizontal beam radiograph of the conscious bearded dragon's skull.


R

Figure 3. Dorsoventral radiograph of the bearded dragon's skull, taken under general anaesthesia.

Food item	Quantity fed, prior to diagnosis	Quantity fed, after diagnosis
Fruit	15g, fed every other day. Banana, mango, berries, grapes, apple, pear, orange	10g, fed in 1cm cubes, twice a week. Apple, pear, pineapple, apricot, peach
Vegetables	15g, fed every other day. Grated carrot, swede, lettuce, broccoli, peppers	20g, fed in 1cm cubes, every other day. Carrot, broccoli, peppers, swede, radish, parsnip
Insects	Fed every other day; 12 mealworms, one or two crickets	Five crickets; three to five locusts; two or three cockroaches
Leaves and weeds	None	Offered when available: dandelion, clover, nasturtium flowers and leaves, bramble leaves
Supplement	On every feed: Nutrobal (Vetark)	On every feed: Nutrobal, (Vetark)

Table 1. Diet and feeding structure of case study patient